

## Structural and Resting-State Brain Connectivity of Motor Networks After Stroke

Alexander Thiel, MD; Shahabeddin Vahdat, PhD

Focal ischemic brain lesions primarily affect circumscribed brain regions and fiber tracts resulting in acute neurological deficits. Secondary damage because of apoptosis, inflammation, diaschisis, and neurodegeneration, however, can also affect remote brain areas and may result in a more widespread perturbation of entire functional networks even in the nonischemic hemisphere. Such network-wide effects may play a role in the development of poststroke cognitive impairment and may impose limits on functional recovery.

Assessing the total effect of all these mechanisms onto the damaged and recovering brain may be clinically useful for better outcome prediction and identification of therapeutic targets because some of those processes (diaschisis and inflammation) are in principle reversible and the strengthening of alternative pathways by targeted intervention may promote recovery. From a practical clinical point of view, imaging methods which can be performed on clinical MRI scanners and do not require active patient participation are ideal candidates to perform such assessments. This topical review thus focuses on diffusion tensor imaging (DTI) MRI and resting-state functional MRI (RS-fMRI) as the most promising methods to this regard (Table). We briefly introduce the physiological background of each method and review current evidence for assessing connectivity in the context of motor recovery.

### Assessing Structural Connectivity With DTI

#### Principles of DTI

Diffusion-based MRI methods are techniques that are sensitive to signals originating from freely moving water molecules in the tissue. Unrestricted movement in all 3 spatial directions results in isotropic diffusion. In the healthy human brain, highly organized white matter pathways consisting of tightly packed axons present a barrier to isotropic diffusion. This diffusion anisotropy is characterized by the preferential diffusion of water molecules parallel to the long axis of the fiber bundles with restricted diffusion perpendicular to the long axis.<sup>1</sup>

During DTI acquisitions, pairs of balanced diffusion-sensitizing field gradients are applied to dephase and then rephase the precessing protons in water molecules, labeling

their translational movement. The net diffusion causes a loss of signal intensity in the final image. A tensor model, which is a 3-dimensional representation of the distance covered in space by water molecules over time, allows the quantification of diffusion along each of the principle axes of the tensor. This diffusivity information can be converted into fractional anisotropy (FA), a scalar value ranging from 0 to 1, which is a sensitive measure of microstructural integrity but not specific for the type of pathology.<sup>2</sup> The diffusion tensor model can also be used to reconstruct fiber tracts in 3 dimensions, thus enabling the *in vivo* visualization of structural connectivity. Tractography algorithms follow the predominant direction of diffusion at each image to determine the anatomic connections but have limitations in resolving regions of crossing white matter pathways.<sup>2</sup>

### Pyramidal Tract Integrity in Chronic Stroke

Decreases in FA have traditionally been interpreted as a correlate of Wallerian degeneration of fiber tracts after stroke.<sup>3</sup> Wallerian degeneration is the anterograde degeneration of axons and their myelin sheaths after proximal axonal injury and most studies traditionally focused on changes in FA of the pyramidal tract (PT) anterograde to the lesion in the chronic phase.<sup>4</sup>

All cross-sectional studies, using FA metrics (either regional FA or FA ratios between identical regions of interest in the affected and nonaffected hemispheres) agree that a decrease in FA at the level of the internal capsule, pons, or cerebral peduncles at 1 month after the event or later correlates with motor impairment in the chronic stage.<sup>5-9</sup> Tractography in those chronic cases indeed demonstrates a reduction of the tract volume, which may be interpreted as atrophy secondary to anterograde degeneration.<sup>10,11</sup> These metrics of PT integrity also seem to better correlate with motor impairment than lesion size alone<sup>12</sup> or task-based fMRI motor network activity<sup>13</sup> but are highly correlated with functional resting-state connectivity.<sup>14</sup> They thus probably better characterize the net damage to the common outflow pathway of distributed motor networks.

Received July 29, 2014; final revision received November 7, 2014; accepted November 11, 2014.

From the Department of Neurology and Neurosurgery (A.T.) and Department of Psychology (S.V.), McGill University, Montreal, Canada; Department of Neuroscience, Jewish General Hospital, Lady Davis Institute for Medical Research, Montreal, Canada (A.T.); and Functional Neuroimaging Unit, Department of Neuroscience, University of Montreal, Montreal, Canada (S.V.).

Correspondence to Alexander Thiel, MD, Jewish General Hospital, Lady Davis Institute for Medical Research, 3755 Cote St Catherine Rd, Montreal H3T 1E2, QC Canada. E-mail alexander.thiel@mcgill.ca

(*Stroke*. 2015;46:296-301. DOI: 10.1161/STROKEAHA.114.006307.)

© 2014 American Heart Association, Inc.

*Stroke* is available at <http://stroke.ahajournals.org>

DOI: 10.1161/STROKEAHA.114.006307

**Table. Comparison of Resting-State fMRI and Diffusion Tensor Imaging**

	RS-fMRI	DTI
Basic principle	Spontaneous fluctuations of BOLD signal	Diffusion restriction of water molecules
Basic measure	Correlations between BOLD signal time course in remote brain areas	Magnitude and direction of diffusion tensor
Preprocessing challenge	Physiological (cardiac, respiratory) artifacts	Resampling of images for alignment
Processing methods	Seed-based correlations Independent component analysis Clustering analysis Graph-based methods	Tractography using deterministic or probabilistic tracing algorithms Graph-based methods
Proposed clinical protocol	180 volumes, 4-mm isotropic voxels, 34 slices, TR=1810 ms, TE=30 ms, flip angle=90° Instruction to patient eyes closed Record respiration and pulse	Sixty-four diffusion encoding directions, 2-mm isotropic voxels, 63 slices, $b=1000$ s/mm <sup>2</sup> , TE=121 ms, TR=11.1 s, flip angle=90°
Limitations	Large amount of noise Influence of image processing steps Variation of networks over time Susceptibility artifacts of sinuses	Fibers crossing main tracing direction Fractional anisotropy is unspecific measure of tract integrity Influence of image processing steps
Advantages	Examine coherent functional networks Independent of task performance Simple scanning protocol with little head motion artifacts	Visualization of anatomic connections Measure of fiber tract integrity

BOLD indicates blood oxygen level dependent; DTI, diffusion tensor imaging; RS-fMRI, resting-state functional MRI; TE, echo time; and TR, repetition time.

### PT Integrity in Acute and Subacute Stroke

Longitudinal studies in homogeneous patient populations with well-defined subcortical infarcts, however, seem to suggest a different interpretation of FA metrics as surrogate marker of degeneration only. By analyzing retrograde and anterograde portions of the PT in patients with subcortical stroke, a significant decrease in FA was demonstrated already in the subacute phase ( $\approx 10$  days after stroke) in both tract portions.<sup>10</sup> This indicates that other processes than neurodegeneration must contribute to these early changes in FA signal and that ischemic damage is likely responsible for these early changes. A degenerative component, mainly affecting the anterograde portion, may contribute to the observed FA decreases only in later stages. A recent longitudinal study found changes in the PT already in the hyperacute phase (<4.5 hours).<sup>15</sup> Interestingly, in these studies, changes in FA in the subacute phase were correlated with the motor deficit in the subacute<sup>10,16,17</sup> and chronic phase<sup>10,18</sup> and indicate that the extent of tract damage at different levels as measured in the acute phase<sup>19</sup> seems to be the determinant of outcome and recovery. Early changes in PT FA and their relationship to functional impairment and rehabilitation outcome are thus of possible clinical relevance for early rehabilitation interventions.

### Role of Alternative Pathways

Besides the corticospinal tract portion of the PT originating from the primary motor cortex, there are also fibers originating from the premotor and supplementary motor cortices, which seem to contribute to the recovery of grip strength.<sup>20</sup> In addition, extrapyramidal pathways may undergo structural changes during the recovery phase, which may constitute adaptive changes in structural connectivity of motor networks. In patients with chronic stroke, FA of the corticorubrospinal tract seems to be increased as compared with control subjects and correlates positively

with upper extremity motor function. Corticorubrospinal tract FA also seems to be inversely related to connectivity of the PT indicating that the more damage has been inflicted to the PT the stronger is the possible compensatory connectivity of extrapyramidal fibers.<sup>21</sup> This correlation occurs only after 3 months, thus supporting the view that these changes are indeed an adaptation of structural connectivity.<sup>22</sup> Although changes in tract volume and FA changes seem to be highly correlated for the PT, dissociation between those metrics of structural connectivity has been reported recently for the corticoreticular pathway, which is an important extrapyramidal pathway for walking ability. In patients with chronic stroke walking ability was correlated with corticoreticular pathway volume in the nonaffected hemisphere and this volume was higher in patients who recovered walking ability than in those who did not and even higher than in normal controls, thus supporting the view that these changes in the non-affected hemisphere might indeed be compensatory.<sup>23</sup>

### Structural Connectivity

Starting with the observation that ischemic strokes involving the primary motor cortex cause an increase in activity in the contralesional motor cortex when moving the paretic limb, callosal motor fibers connecting both motor cortices are considered the anatomic substrate for this phenomenon based on the theory of poststroke transcallosal disinhibition.<sup>24</sup> Using tractography to isolate callosal motor fibers in patients with subcortical stroke at the level of the internal capsule, it was shown that FA ratios in callosal motor fibers were decreased relative to callosal optical fibers in the same subjects and to callosal motor fibers in controls<sup>25</sup> in the chronic but not in the subacute phase. These signal changes in the corpus callosum seem to indicate transsynaptic degeneration related to upper extremity motor function<sup>26</sup> and may be clinically useful in

predicting a patient's individual response to therapeutic intervention.<sup>27</sup> Although these tractography studies may be informative, they do require tracing of individual tracts between seed regions and may thus not yet be applicable for routine clinical use. Approaches that try to automatically map all possible fiber tract connections (the connectome) using voxelwise connectivity matrices<sup>28</sup> or try to estimate remote stroke effects from normal connectivity maps<sup>29</sup> may be promising alternatives to tractography, but require further exploration.

## Assessing Functional Connectivity With RS-fMRI

### Physiology of RS-fMRI

Spontaneous modulations of fMRI signal in the absence of any overt task or stimulation is referred to as RS-fMRI. Blood oxygen level–dependent contrast is by far the most widely used fMRI technique to measure hemodynamic responses related to neural activity. An increasing body of evidence indicates that spontaneously occurring blood oxygen level–dependent fluctuations at infraslow frequency bands (0.01–0.1 Hz) are not simply noise, but rather reveal synchronized spatiotemporal organization of the brain at rest.<sup>30</sup> These slow fluctuations partition the resting brain into temporally synchronized networks of spatially distinct areas, the so-called resting-state networks (RSNs). Specifically, the spatial pattern of RSNs mimics clusters of brain regions that are coactivated during the performance of different sensorimotor and cognitive tasks.<sup>30</sup> Although the relationship between RS-fMRI and neural activity is not yet fully understood, several lines of evidence support significant neural contributions to RS-fMRI fluctuations. Infraslow fluctuations of RS-fMRI are directly correlated with the same frequency range fluctuations in the power of fast (gamma range) local field potentials.<sup>31</sup>

Functional connectivity (FC) analysis measures correlations between fMRI time points of remote brain areas. FC analysis estimates how well the blood oxygen level–dependent time-series of different regions covary and measures the strength of relationship between them. There are mainly 4 different analytic techniques for performing resting-state FC analysis, including seed-based correlations, independent component analysis, clustering analysis, and graph-based methods. For a detailed comparison, see Lee et al.<sup>32</sup>

Resting-state FC analysis, in particular, is suited to study large-scale functional network dynamics and reorganization under normal and diseased conditions for the following reasons: first, in contrast to the task-based fMRI, they are not subject to changes in task parameters over time (eg, as a result of learning or recovery) and thus allow evaluation of functional networks under similar experimental conditions. Second, the RSNs allow to study more long-term effects of training or recovery that are beyond the periods of task performance.<sup>33,34</sup> Finally, even patients with severe disabilities can undergo resting-state scans without causing excessive motion artifacts, which potentially degrade image quality. Limitations of RS-fMRI include low signal:noise ratio because of artifacts from respiratory and cardiac activity as well as influence of image processing steps (such as selection of seed voxels and band-pass filtering) on connectivity measures.

## RSNs Reorganization After Stroke

### Acute Phase

Several studies have examined RSNs spatiotemporal patterns in patients with acute stroke in relation to the degree of motor deficit and compared with controls.<sup>35–37</sup> The consistent finding is that the interhemispheric FC between homologous sensory and motor areas is decreased compared with controls and is correlated with the degree of behavioral impairments in the acute stage.<sup>35–39</sup> It has been shown<sup>35</sup> that acute disruption of interhemispheric resting-state FC in the dorsal attention and somatomotor RSNs correlates with behavioral measures of attention and motor impairments. Similar findings have been reported in a rat stroke model, demonstrating a link between sensorimotor impairments and deterioration of interhemispheric connectivity.<sup>37</sup> In contrast to nonrecovered patients with motor deficits, patients with acute stroke without motor impairment and subacute-recovered patients showed normal connectivity between ipsilesional and contralesional motor cortices.<sup>38</sup> In another combined resting-state and passive movement study,<sup>40</sup> reduced interhemispheric connectivity in the acute stage could differentiate patients with poor from patients with good recovery. This close correspondence between the degree of impairment/recovery and reduced interhemispheric connectivity suggests that a tightly controlled balance between excitatory and inhibitory connections across hemispheres is necessary for optimal execution of sensorimotor function.<sup>41</sup>

Higher connectivity in the acute phase between ipsilesional motor cortex and contralesional thalamus and supplementary motor area was predictive of a better chronic motor recovery<sup>39</sup> as was the progressive restoration<sup>42</sup> of interhemispheric, but not intrahemispheric somatomotor connectivity.

### Subacute Phase

Although the acutely diminished interhemispheric connectivity is progressively increasing during the subacute phase together with functional recovery, it does not reach the connection strength of control subjects.<sup>36,42</sup> This subacute FC deficit is well correlated with reduced white matter integrity in corpus callosum and ipsilesional PT as measured by DTI<sup>37</sup> or manganese-enhanced MRI.<sup>43</sup> This suggests that functional and neuroanatomical connectivity deteriorations are 2 sides of the same medal, directly contributing to poststroke behavioral deficits.

Moreover, several studies have examined changes in the topology of RSNs to assess network reorganization during the subacute phase. Using graph theory–based RS-fMRI analysis, the small world-ness of somatomotor networks is evaluated after experimental<sup>24</sup> and human<sup>16</sup> stroke. Small world topology is characterized by high clustering and short path length within a network, yielding fast propagation of information and strong synchronizability between network nodes.<sup>44,45</sup> The results of these attempts, however, are inconsistent with 1 study describing a decrease in small world properties of the reorganized motor network toward a random configuration,<sup>36</sup> whereas another one documented an increase in small world-ness within the bilateral network, which tends to return to a baseline small-world topology at chronic stages.<sup>46</sup>

Thus, the interpretation of results in the former case would suggest that random spontaneous axonal outgrowth is the mechanistic feature of less optimal network reorganization, whereas

the latter supports the view that an optimal strategy aims at reorganization of large-scale networks to achieve faster information transfer, as well as higher local processing power after stroke.

Another subacute signature of RSN reorganization is intrahemispheric connectivity changes within the ipsilesional and contralesional sensorimotor regions. Subacute-decreased ipsilateral intrahemispheric connectivity is demonstrated after large cortical and subcortical infarcts in rats<sup>37</sup> and increased intrahemispheric connectivity was reported within contralesional sensorimotor cortex. These changes in intrahemispheric connectivity, however, did not correlate with restoration of motor function.<sup>42</sup> Overall, although decreased ipsilesional and increased contralesional intrahemispheric connectivity patterns have been documented, lack of any relationship with functional outcome measures suggests a minor impact of mechanisms to motor recovery in the subacute phase.

### Chronic Phase

The transition to the chronic poststroke phase is characterized by a gradual normalization of connectivity patterns toward prestroke RSN connectivity. For example, decreased interhemispheric connectivity between homologous areas tends to return back to normal in patients who recovered well, whereas in poorly recovered patients, the degree of decreased interhemispheric connectivity correlates with motor function.<sup>26,42,47</sup> This reduction in interhemispheric connectivity coincided with reduced structural integrity of transcallosal motor fibers and PT.<sup>26</sup> Both, structural and FC measures, were independently correlated with clinical outcome measurements, suggesting that both measures may provide complementary information.

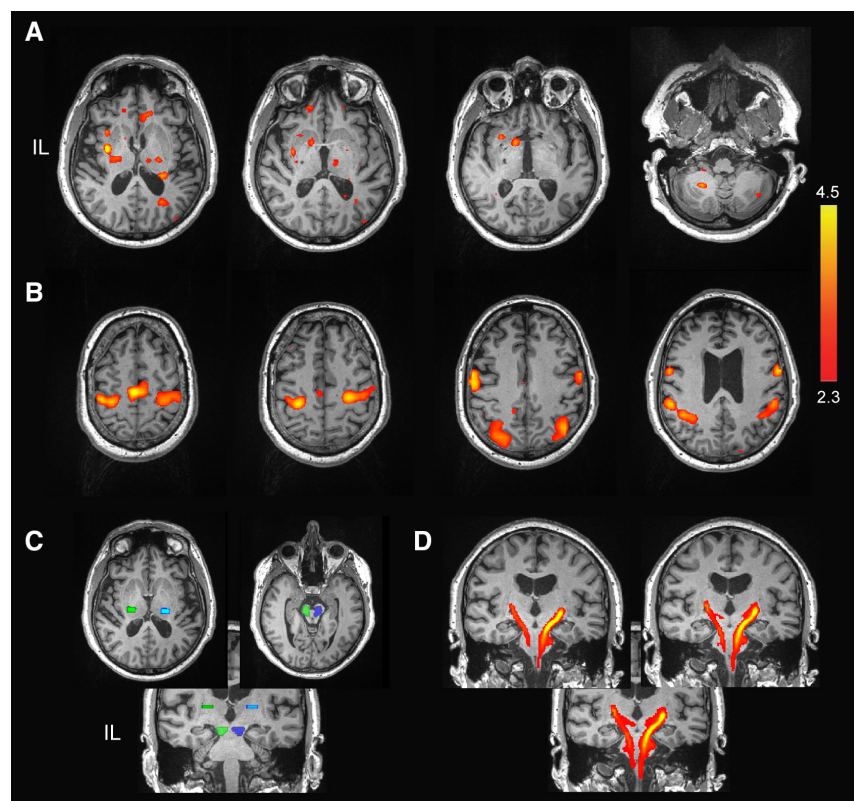
Reorganization of RSN connectivity in the chronic phase also seems to extend to RSNs, which are not directly involved

in sensory-motor processing. A non-hypothesis-driven independent component analysis decomposition of RSNs in patients with chronic stroke<sup>48</sup> found elevated intranetwork connectivity in different sensory, motor, and default mode networks compared with controls, but connectivity was decreased within associative frontoparietal networks and between networks. These findings partly suggest that RSNs reorganization in the chronic stage involves higher integration within networks than across.

To date, changes in the RSNs spatiotemporal patterns have been investigated after spontaneous recovery of sensorimotor function. The effect of therapeutic intervention on RSN connectivity remains to be studied. Vahdat et al<sup>33</sup> have recently documented learning-induced changes in RSNs after motor and perceptual<sup>34</sup> training, which were associated with improvements in behavioral task performance in healthy subjects.<sup>49</sup> The Figure shows changes in the RSNs after 1 hour of similar somatosensory perceptual training in a patient with chronic subcortical stroke. Two RSNs were activated as a result of perceptual learning: a sensory network (Figure [A]) including bilateral thalamus cerebellum and ipsilesional striatum, as well as a motor-related network (Figure [B]). Structural connectivity as measured with DWI showed a decrease in both FA and PT volume in the affected hemisphere (Figure [C and D]). Training-induced changes in FA, however, were not significant. RS-fMRI connectivity analysis may thus provide information on a patient's responsiveness to different rehabilitation interventions.

### Conclusions

At present, assessment of structural integrity of the entire PT as common motor output pathway and assessment of interhemispheric resting-state connectivity between motor



**Figure.** Changes of structural and functional connectivity after sensory training. **A** and **B**, Resting-state networks showing increased connectivity in the post-training condition. A sensory (**A**) and a motor-related (**B**) networks were extracted using shared and specific independent component analysis method. The perceptual training task involved patient's judgment about the movement direction of the affected arm applied passively by a robotic manipulator in the absence of visual feedback. Color bar indicates Z scores. **C**, Seed regions used for diffusion tensor imaging analysis in the posterior limb of the internal capsule and cerebral peduncle in the affected (green) and nonaffected (blue) hemispheres. **D**, Results of corticospinal tractography. IL indicates ipsilesional.

network regions seem to be the clinically most promising MRI approaches for the prognosis of motor stroke recovery. Using connectivity parameters as prognostic indicators may prove useful in the future for stratifying patients for clinical recovery trials. Assessment of interhemispheric connectivity will gain in importance in the context of therapeutic approaches that aim at modulating interhemispheric connectivity (eg, repetitive transcranial magnetic stimulation, transcranial direct current stimulation, or constrained-induced movement therapy) to facilitate motor recovery. However, larger scale clinical trials with robust and easy to implement image acquisition and analysis procedures are now the next step toward a clinical application.

## Disclosures

Dr Thiel received funding from Canadian Institutes for Health Research and Fondation pour la Recherche en Santé du Québec. The other author reports no conflicts.

## References

- Beaulieu C. The basis of anisotropic water diffusion in the nervous system - a technical review. *NMR Biomed*. 2002;15:435-455. doi:10.1002/nbm.782.
- Alexander AL, Lee JE, Lazar M, Field AS. Diffusion tensor imaging of the brain. *Neurotherapeutics*. 2007;4:316-329. doi:10.1016/j.nurt.2007.05.011.
- Thomalla G, Glauche V, Koch MA, Beaulieu C, Weiller C, Röther J. Diffusion tensor imaging detects early Wallerian degeneration of the pyramidal tract after ischemic stroke. *Neuroimage*. 2004;22:1767-1774. doi:10.1016/j.neuroimage.2004.03.041.
- Lai C, Zhou HC, Ma XH, Zhang HX. Quantitative evaluation of the axonal degeneration of central motor neurons in chronic cerebral stroke with diffusion tensor imaging. *Acta Radiol*. 2014;55:114-120. doi:10.1177/0284185113492456.
- Globas C, Lam JM, Zhang W, Imanbayev A, Hertler B, Becker C, et al. Mesencephalic corticospinal atrophy predicts baseline deficit but not response to unilateral or bilateral arm training in chronic stroke. *Neurorehabil Neural Repair*. 2011;25:81-87. doi:10.1177/1545968310382001.
- Jason E, Dastidar P, Kalliokoski A, Luukkaala T, Soimakallio S. Diffusion tensor imaging of chronic cerebral hemisphere infarctions. *J Neuroimaging*. 2011;21:325-331. doi:10.1111/j.1552-6569.2010.00513.x.
- Song F, Zhang F, Yin DZ, Hu YS, Fan MX, Ni HH, et al. Diffusion tensor imaging for predicting hand motor outcome in chronic stroke patients. *J Int Med Res*. 2012;40:126-133.
- Puig J, Blasco G, Daunis-I-Estadella J, Thomalla G, Castellanos M, Figueras J, et al. Decreased corticospinal tract fractional anisotropy predicts long-term motor outcome after stroke. *Stroke*. 2013;44:2016-2018. doi:10.1161/STROKEAHA.111.000382.
- Jang SH, Kim K, Kim SH, Son SM, Jang WH, Kwon HG. The relation between motor function of stroke patients and diffusion tensor imaging findings for the corticospinal tract. *Neurosci Lett*. 2014;572:1-6. doi:10.1016/j.neulet.2014.04.044.
- Radlinska B, Ghinani S, Leppert IR, Minuk J, Pike GB, Thiel A. Diffusion tensor imaging, permanent pyramidal tract damage, and outcome in subcortical stroke. *Neurology*. 2010;75:1048-1054. doi:10.1212/WNL.0b013e3181f39aa0.
- Lindenberg R, Renga V, Zhu LL, Betzler F, Alsop D, Schlaug G. Structural integrity of corticospinal motor fibers predicts motor impairment in chronic stroke. *Neurology*. 2010;74:280-287. doi:10.1212/WNL.0b013e3181ccc6d9.
- Sterr A, Dean PJ, Szameitat AJ, Conforto AB, Shen S. Corticospinal tract integrity and lesion volume play different roles in chronic hemiparesis and its improvement through motor practice. *Neurorehabil Neural Repair*. 2014;28:335-343. doi:10.1177/1545968313510972.
- Qiu M, Darling WG, Morecraft RJ, Ni CC, Rajendra J, Butler AJ. White matter integrity is a stronger predictor of motor function than BOLD response in patients with stroke. *Neurorehabil Neural Repair*. 2011;25:275-284. doi:10.1177/1545968310389183.
- Jayaram G, Stagg CJ, Esser P, Kischka U, Stinear J, Johansen-Berg H. Relationships between functional and structural corticospinal tract integrity and walking post stroke. *Clin Neurophysiol*. 2012;123:2422-2428. doi:10.1016/j.clinph.2012.04.026.
- Puig J, Blasco G, Daunis-I-Estadella J, Thomalla G, Castellanos M, Soria G, et al. Increased corticospinal tract fractional anisotropy can discriminate stroke onset within the first 4.5 hours. *Stroke*. 2013;44:1162-1165. doi:10.1161/STROKEAHA.111.678110.
- Liu X, Tian W, Li L, Kolar B, Qiu X, Chen F, et al. Hyperintensity on diffusion weighted image along ipsilateral cortical spinal tract after cerebral ischemic stroke: a diffusion tensor analysis. *Eur J Radiol*. 2012;81:292-297. doi:10.1016/j.ejrad.2010.12.053.
- Koyama T, Marumoto K, Miyake H, Domen K. Relationship between diffusion tensor fractional anisotropy and motor outcome in patients with hemiparesis after corona radiata infarct. *J Stroke Cerebrovasc Dis*. 2013;22:1355-1360. doi:10.1016/j.jstrokecerebrovasdis.2013.02.017.
- Groisser BN, Copen WA, Singhal AB, Hirai KK, Schaechter JD. Corticospinal tract diffusion abnormalities early after stroke predict motor outcome. *Neurorehabil Neural Repair*. 2014;28:751-760. doi:10.1177/1545968314521896.
- Puig J, Pedraza S, Blasco G, Daunis-I-Estadella J, Prados F, Remollo S, et al. Acute damage to the posterior limb of the internal capsule on diffusion tensor tractography as an early imaging predictor of motor outcome after stroke. *AJNR Am J Neuroradiol*. 2011;32:857-863. doi:10.3174/ajnr.A2400.
- Schulz R, Park CH, Boudrias MH, Gerloff C, Hummel FC, Ward NS. Assessing the integrity of corticospinal pathways from primary and secondary cortical motor areas after stroke. *Stroke*. 2012;43:2248-2251. doi:10.1161/STROKEAHA.112.662619.
- Rüber T, Schlaug G, Lindenberg R. Compensatory role of the cortico-rubro-spinal tract in motor recovery after stroke. *Neurology*. 2012;79:515-522. doi:10.1212/WNL.0b013e31826356e8.
- Takenobu Y, Hayashi T, Moriwaki H, Nagatsuka K, Naritomi H, Fukuyama H. Motor recovery and microstructural change in subcortical tract in subcortical stroke. *Neuroimage Clin*. 2014;4:201-208. doi:10.1016/j.nicl.2013.12.003.
- Jang SH, Chang CH, Lee J, Kim CS, Seo JP, Yeo SS. Functional role of the corticoreticular pathway in chronic stroke patients. *Stroke*. 2013;44:1099-1104. doi:10.1161/STROKEAHA.111.000269.
- van der Knaap LJ, van der Ham IJ. How does the corpus callosum mediate interhemispheric transfer? A review. *Behav Brain Res*. 2011;223:211-221. doi:10.1016/j.bbr.2011.04.018.
- Radlinska BA, Blunk Y, Leppert IR, Minuk J, Pike GB, Thiel A. Changes in callosal motor fiber integrity after subcortical stroke of the pyramidal tract. *J Cereb Blood Flow Metab*. 2012;32:1515-1524. doi:10.1038/jcbfm.2012.37.
- Chen JL, Schlaug G. Resting state interhemispheric motor connectivity and white matter integrity correlate with motor impairment in chronic stroke. *Front Neurol*. 2013;4:178. doi:10.3389/fneur.2013.00178.
- Lindenberg R, Zhu LL, Rüber T, Schlaug G. Predicting functional motor potential in chronic stroke patients using diffusion tensor imaging. *Hum Brain Mapp*. 2012;33:1040-1051. doi:10.1002/hbm.21266.
- Kalinosky BT, Schindler-Ivens S, Schmit BD. White matter structural connectivity is associated with sensorimotor function in stroke survivors. *Neuroimage Clin*. 2013;2:767-781. doi:10.1016/j.nicl.2013.05.009.
- Kuceyeski A, Kamel H, Navi BB, Raj A, Iadecola C. Predicting future brain tissue loss from white matter connectivity disruption in ischemic stroke. *Stroke*. 2014;45:717-722. doi:10.1161/STROKEAHA.113.003645.
- Fox MD, Raichle ME. Spontaneous fluctuations in brain activity observed with functional magnetic resonance imaging. *Nat Rev Neurosci*. 2007;8:700-711. doi:10.1038/nrn2201.
- Leopold DA, Maier A. Ongoing physiological processes in the cerebral cortex. *Neuroimage*. 2012;62:2190-2200. doi:10.1016/j.neuroimage.2011.10.059.
- Lee MH, Smyser CD, Shimony JS. Resting-state fMRI: a review of methods and clinical applications. *AJNR Am J Neuroradiol*. 2013;34:1866-1872. doi:10.3174/ajnr.A3263.
- Vahdat S, Darainy M, Milner TE, Ostry DJ. Functionally specific changes in resting-state sensorimotor networks after motor learning. *J Neurosci*. 2011;31:16907-16915. doi:10.1523/JNEUROSCI.2737-11.2011.
- Vahdat S, Darainy M, Ostry DJ. Structure of plasticity in human sensory and motor networks due to perceptual learning. *J Neurosci*. 2014;34:2451-2463. doi:10.1523/JNEUROSCI.4291-13.2014.
- Carter AR, Astafiev SV, Lang CE, Connor LT, Rengachary J, Strube MJ, et al. Resting interhemispheric functional magnetic resonance imaging connectivity predicts performance after stroke. *Ann Neurol*. 2010;67:365-375. doi:10.1002/ana.21905.
- Wang L, Yu C, Chen H, Qin W, He Y, Fan F, et al. Dynamic functional reorganization of the motor execution network after stroke. *Brain*. 2010;133(pt 4):1224-1238. doi:10.1093/brain/awq043.

37. van Meer MP, van der Marel K, Wang K, Otte WM, El Bouazati S, Roeling TA, et al. Recovery of sensorimotor function after experimental stroke correlates with restoration of resting-state interhemispheric functional connectivity. *J Neurosci*. 2010;30:3964–3972. doi:10.1523/JNEUROSCI.5709-09.2010.
38. Golestani AM, Tymchuk S, Demchuk A, Goodyear BG; VISION-2 Study Group. Longitudinal evaluation of resting-state fMRI after acute stroke with hemiparesis. *Neurorehabil Neural Repair*. 2013;27:153–163. doi:10.1177/1545968312457827.
39. Park CH, Chang WH, Ohn SH, Kim ST, Bang OY, Pascual-Leone A, et al. Longitudinal changes of resting-state functional connectivity during motor recovery after stroke. *Stroke*. 2011;42:1357–1362. doi:10.1161/STROKEAHA.110.596155.
40. Jung TD, Kim JY, Seo JH, Jin SU, Lee HJ, Lee SH, et al. Combined information from resting-state functional connectivity and passive movements with functional magnetic resonance imaging differentiates fast late-onset motor recovery from progressive recovery in hemiplegic stroke patients: a pilot study. *J Rehabil Med*. 2013;45:546–552. doi:10.2340/16501977-1165.
41. Grefkes C, Fink GR. Connectivity-based approaches in stroke and recovery of function. *Lancet Neurol*. 2014;13:206–216. doi:10.1016/S1474-4422(13)70264-3.
42. Xu H, Qin W, Chen H, Jiang L, Li K, Yu C. Contribution of the resting-state functional connectivity of the contralesional primary sensorimotor cortex to motor recovery after subcortical stroke. *PLoS One*. 2014;9:e84729. doi:10.1371/journal.pone.0084729.
43. van Meer MP, van der Marel K, Otte WM, Berkelbach van der Sprenkel JW, Dijkhuizen RM. Correspondence between altered functional and structural connectivity in the contralesional sensorimotor cortex after unilateral stroke in rats: a combined resting-state functional MRI and manganese-enhanced MRI study. *J Cereb Blood Flow Metab*. 2010;30:1707–1711. doi:10.1038/jcbfm.2010.124.
44. Watts DJ, Strogatz SH. Collective dynamics of ‘small-world’ networks. *Nature*. 1998;393:440–442. doi:10.1038/30918.
45. Hong H, Choi MY, Kim BJ. Synchronization on small-world networks. *Phys Rev E Stat Nonlin Soft Matter Phys*. 2002;65(2 pt 2):026139.
46. van Meer MP, Otte WM, van der Marel K, Nijboer CH, Kavelaars A, van der Sprenkel JW, et al. Extent of bilateral neuronal network reorganization and functional recovery in relation to stroke severity. *J Neurosci*. 2012;32:4495–4507. doi:10.1523/JNEUROSCI.3662-11.2012.
47. Urbin MA, Hong X, Lang CE, Carter AR. Resting-state functional connectivity and its association with multiple domains of upper-extremity function in chronic stroke. *Neurorehabil Neural Repair*. 2014;28:761–769. doi:10.1177/1545968314522349.
48. Wang C, Qin W, Zhang J, Tian T, Li Y, Meng L, et al. Altered functional organization within and between resting-state networks in chronic subcortical infarction. *J Cereb Blood Flow Metab*. 2014;34:597–605. doi:10.1038/jcbfm.2013.238.
49. Guerra-Carrillo B, Mackey AP, Bunge SA. Resting-state fMRI: a window into human brain plasticity. *Neuroscientist*. 2014;20:522–533. doi:10.1177/1073858414524442.

---

KEY WORDS: diffusion tensor imaging ■ functional magnetic resonance imaging ■ pyramidal tracts ■ recovery of function ■ stroke

## Structural and Resting-State Brain Connectivity of Motor Networks After Stroke Alexander Thiel and Shahabeddin Vahdat

*Stroke*. 2015;46:296-301; originally published online December 4, 2014;  
doi: 10.1161/STROKEAHA.114.006307

*Stroke* is published by the American Heart Association, 7272 Greenville Avenue, Dallas, TX 75231  
Copyright © 2014 American Heart Association, Inc. All rights reserved.  
Print ISSN: 0039-2499. Online ISSN: 1524-4628

The online version of this article, along with updated information and services, is located on the  
World Wide Web at:

<http://stroke.ahajournals.org/content/46/1/296>

**Permissions:** Requests for permissions to reproduce figures, tables, or portions of articles originally published in *Stroke* can be obtained via RightsLink, a service of the Copyright Clearance Center, not the Editorial Office. Once the online version of the published article for which permission is being requested is located, click Request Permissions in the middle column of the Web page under Services. Further information about this process is available in the [Permissions and Rights Question and Answer](#) document.

**Reprints:** Information about reprints can be found online at:  
<http://www.lww.com/reprints>

**Subscriptions:** Information about subscribing to *Stroke* is online at:  
<http://stroke.ahajournals.org/subscriptions/>